

Reconstruction of an Extensive Midfacial Defect Using Additive Manufacturing Techniques

Nelson Fernandes, BDS,¹ Jacobus van den Heever, BChD, MChD (Pros),¹ Christiaan Hoogendijk, MBChB, BChD, MChD (Chir. MaxFac Med), FCMFOS (SA),² Sarel Botha, MBChB, BChD, Dip Odont (oral surg), MBA, MChD (MFOS), FCMFOS (SA),² Gerrie Booysen, M.Tech (Eng Mech),³ & Johan Els, B.Med.Sc (Hons)³

¹Department of Prosthodontics, School of Dentistry, Faculty of Health Sciences, University of Pretoria, South Africa

²Department of Maxillofacial and Oral Surgery, School of Dentistry, Faculty of Health Sciences, University of Pretoria, South Africa

³Centre of Rapid Prototyping and Manufacturing, Central University of Technology, Bloemfontein, South Africa

Keywords

Rapid prototyping; 3D printing; facial prosthesis; malignant peripheral nerve sheath tumors.

Correspondence

Nelson Fernandes, BDS, Department of Prosthodontics, PO Box 1266, Pretoria, 0001, South Africa. E-mail: nelsondentist@gmail.com

This work was presented as a poster presentation by Dr J Van Der Heever from May 15–17, 2014 at the "Oncologic Dentistry and Maxillofacial Prosthetics Symposium," University of Texas, Houston, TX.

No conflict of interest declared.

Accepted February 27, 2016

doi: 10.1111/jopr.12487

Abstract

Malignant peripheral nerve sheath tumors are extremely rare tumors arising in peripheral nerves. Only 17 cases involving the trigeminal nerve have ever been reported. These tumors have a very poor prognosis and very high rates of recurrence and metastases. Their recommended treatment involves complete tumor resection followed by radiation. This can be problematic in the head and neck region. We present a clinical case involving a 33-year-old female patient presenting with a slow-growing, exophytic mass of the anterior maxilla. Incisional biopsy and subsequent histological examination revealed a diagnosis of a malignant peripheral nerve sheath tumor. Surgical resection involved a complete maxillectomy, rhinectomy, and resection of the upper lip and aspects of the left and right cheeks. Reconstruction of the subsequent defect incorporated the placement of four zygomatic oncology implants to aid in retention of a facial prosthesis. These implants, however, were subsequently lost; and an anatomical model of the hard tissues was manufactured via 3D printing. This model was used to design and manufacture a titanium frame (customized implant) for the patient. The frame was then fixated and secured intraoperatively with 21 cortical screws. A maxillary denture and silicone facial prosthesis were also made to fit onto this frame. This is the first known case where additive manufacturing, via the use of rapid prototyping and 3D printing, was employed to manufacture a facial prosthesis.

Malignant peripheral nerve sheath tumors (MPNSTs) are extremely rare tumors arising from the Schwann cells of peripheral nerves.¹ MPNSTs of the trigeminal nerve are exceedingly rare¹ with only 17 cases being published in the English medical literature.^{2,5,6} These tumors have a very poor prognosis¹ with 5-year survival rates of only 20% being reported in the head and neck region.^{1,8} Local recurrence rates range from 30% to 60% even in cases of complete tumor resection.^{1,3,7} They have been shown to metastasize to the lungs, soft tissue, bone, liver, and/or brain in almost 65% of cases.^{1-3,10}

Due to their aggressive and highly infiltrative nature,¹ high recurrence rate,^{1,3} and poor prognosis, the recommended treatment for these tumors is aggressive radical resection.^{1,2,5,11} Complete removal of the lesion with tumor-free margins^{3,4,9,10} measuring 2 cm in all directions is seldom possible in the head and neck region, therefore radiation therapy following resection is recommended. This could offer increased rates of tumor control and long-term survival.^{1,2,8,9,11}

Clinical report

We present the case of a 33-year-old female patient who presented in 2011 with a slow-growing exophytic soft tissue mass of the anterior maxilla in the region of teeth #s 11, 12, 13, 21, and 22 and spreading to the palate. A biopsy of the lesion was performed and histologically diagnosed as Kaposi sarcoma. The patient was referred for chemotherapy but never received this treatment and no follow-up appointments were scheduled.

The patient returned a few months later in 2012 presenting with an anterior palatal mass, measuring 12×10×8 mm, infiltrating the underlying maxilla. The lesion appeared to be secondarily infected, with signs and symptoms of continuous bleeding and occasional pain. An incisional biopsy was submitted for histological evaluation, which revealed a diagnosis of a malignant peripheral nerve sheath tumor. This required that the anterior portion of the maxilla be surgically resected, including

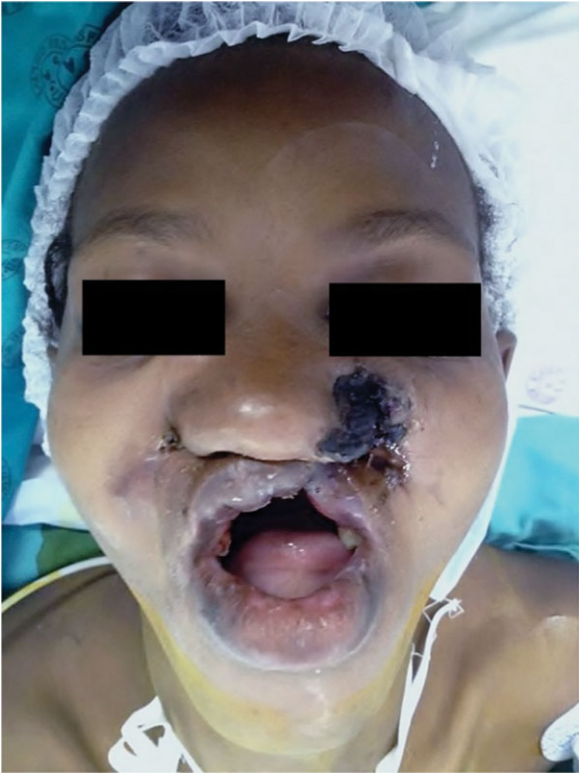

Figure 1 Malignant peripheral nerve sheath tumor of the face.

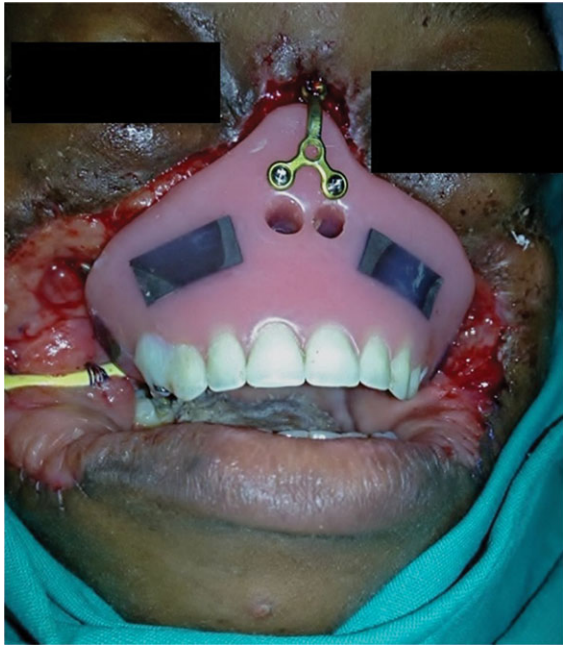


Figure 3 Provisional implant-supported acrylic obturator.

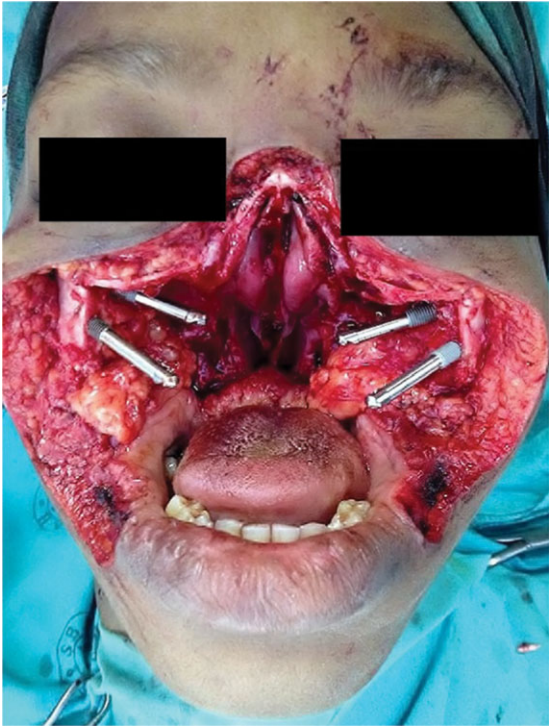

Figure 2 Oncology implants placed at time of resection.

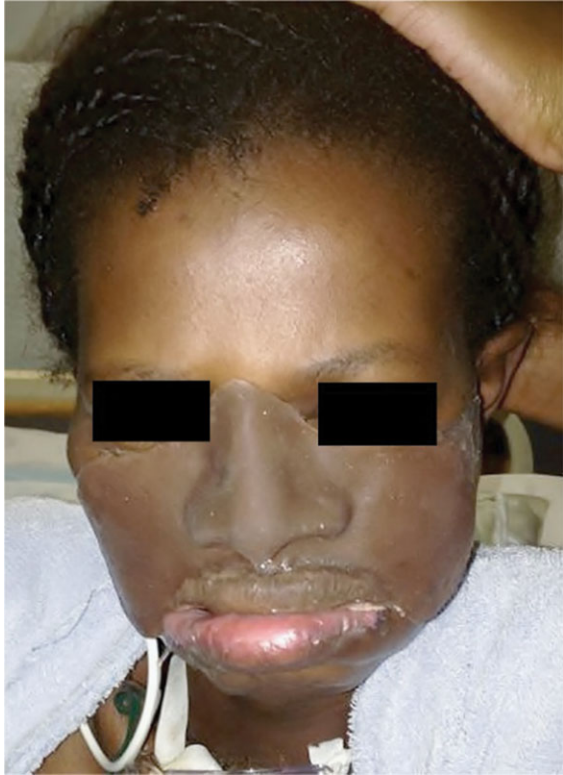

Figure 4 Interim facial prosthesis.

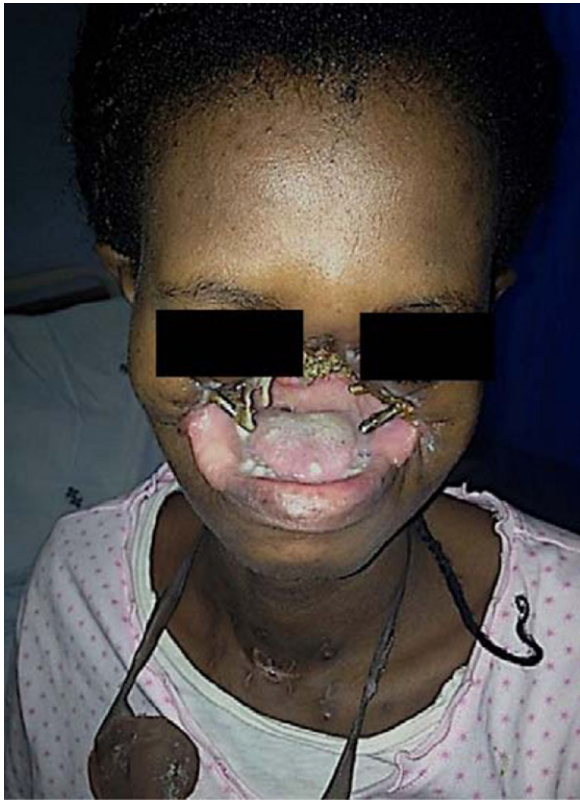

Figure 5 Defect after loss of implants.

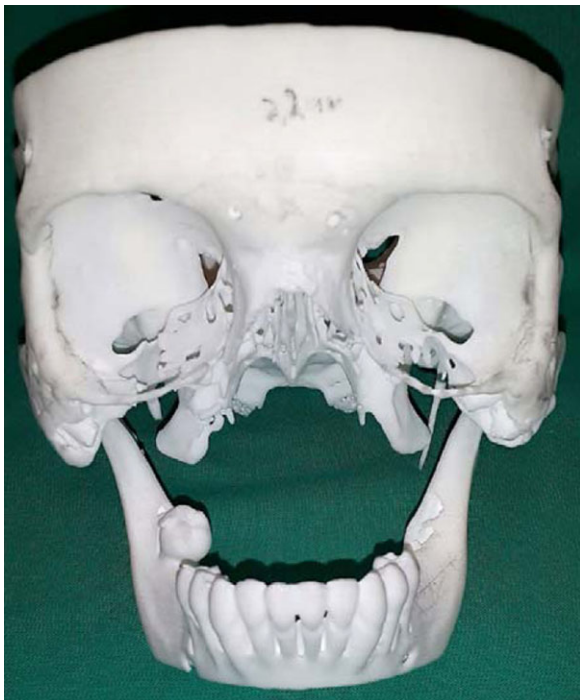

Figure 6 Frontal view of 3D planning model indicating the severity of the defect.

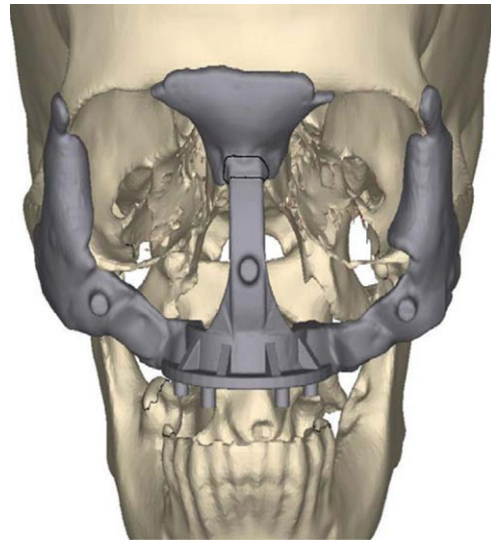


Figure 7 Final 3D CAD design of titanium implant.

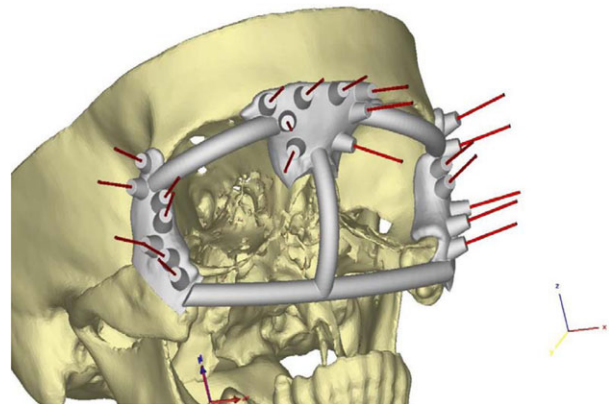


Figure 8 3D design of drill guide with drilling angles indicated by the red lines.

all the anterior teeth, premolars, and the body of the maxilla up to 2 cm above the nasal floor.

The patient was once again non-compliant, so surgery and prosthesis fabrication were not performed at this time. She did return in 2013, presenting with tumor infiltration involving the left and right alae and the right cheek, as well as an ulcerated lesion of the upper lip, causing considerable pain and discomfort. An incisional biopsy and subsequent histological examination revealed a diagnosis of a recurrent malignant peripheral nerve sheath tumor (Fig 1).

This tumor was extending rapidly, and due to a history of non-compliance by the patient, we had to act quickly. Our team, comprising two maxillofacial surgeons and a prosthodontist, planned for the surgical excision of the tumor in its entirety.

Maxillectomy defects

Maxillectomy defects resulting from resective surgery can be divided into the following types:¹²



Figure 9 Polished midfacial titanium implant.

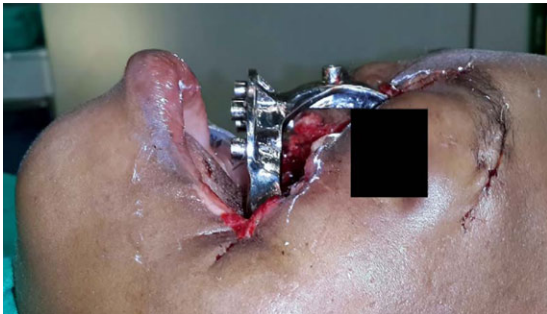

Figure 10 Implant immediately postsurgery.

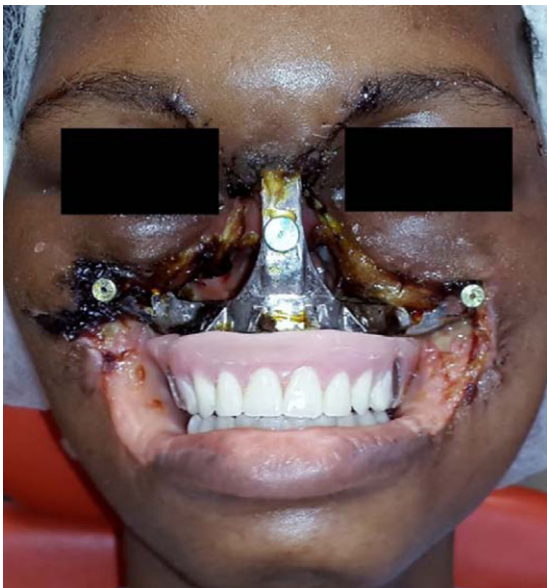


Figure 11 Maxillary denture with soft base fitting surface.

- Type I—limited maxillectomy defects—partial defects where the palate and orbital floor remain intact.
- Type II—subtotal maxillectomy defects—involve resection of most of the maxilla, but the orbital floor remains intact. In type IIA, the defect incorporates less than 50%

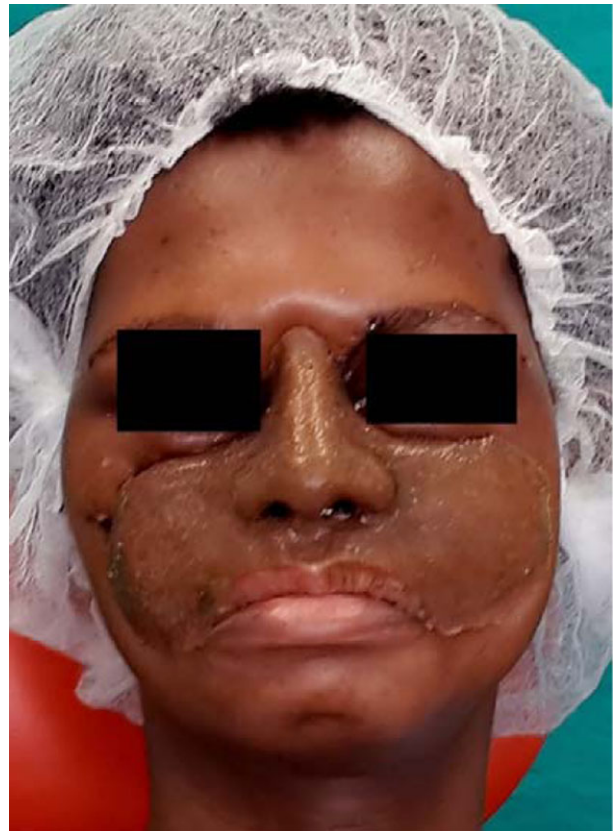

Figure 12 Silicone facial prosthesis.

of the palate, while in type IIB, the defect extends over more than 50% of the palate.

- Type III—total maxillectomy defects—involve resection of the entire maxilla, and can exclude (type IIIA) or include (type IIIB) the orbital contents.
- Type IV—orbitomaxillectomy defects—involve resection of the upper part of the maxilla and orbital contents with the palate remaining largely intact.

Due to its extent, a subtotal maxillectomy, rhinectomy, and resection of the upper lip including some aspects of the left and right cheeks would have to be performed. This placed our patient in the type IIB category, because the resultant defect included the entire palate but the orbital floor and its contents remained in place.

Reconstruction of such a defect should ideally be done immediately or very soon after the resective procedure, to minimize psychological and emotional distress on the patient. The considerable gains in microvascular surgical techniques in the past 20 to 30 years have allowed surgeons to be able to reconstruct significant defects like these in a single procedure. The use of pedicle flaps from the surrounding regions and free tissue transfers, including hard and soft tissues, from sites such as the radial forearm, rectus abdominus, fibula, scapular region, and the iliac crest, have given surgeons the ability to customize their reconstructions to match defects.¹³

Surgical reconstruction of such a significant defect would have required an additional team of reconstructive and microvascular surgeons. Unfortunately, the public health service in South Africa lacks these highly specialized surgeons. It was thus decided to reconstruct the defect via an extensive maxillofacial prosthodontic rehabilitation. No prior facial impressions were made before surgery due to a lack of available chair time in our prosthodontic ward. Following the resective surgery, our maxillofacial surgeons placed four zygomatic oncology implants (Southern Implants, Pretoria, South Africa). This was planned to aid in the retention of our prosthesis. At the same time, and still in the operating theater, our prosthodontist took an impression of the defect and the position of the implants (Fig 2).

Zygomatic implants are 35 to 55 mm long and are inserted into the zygomatic bone. As a result of this increased length, any movements on the implants will have significant leveraging effects at their point of insertion, which could interfere with osseointegration. At our institution, we try to splint these implants as quickly as possible. A modified interim implant-supported obturator prosthesis and interim silicone facial prosthesis were manufactured and placed 3 days after surgery to establish separate oral and nasal cavities to improve swallowing, facilitate saliva control, and enhance speech articulation (Figs 3 and 4).

As a possible result of immediate loading on these implants and the extensive size of the prosthesis loaded onto them, they failed to osseointegrate and were lost after 4 weeks. This meant that the obturator had to be removed (Fig 5). This posed a major complication for the fabrication of a new prosthesis. The tissues bordering the defect had no bony foundation, and were easily compressed and distorted, which made subsequent impression taking virtually impossible. Traditional and conventional means for reconstruction were no longer an option, so we decided to incorporate advanced technology to assist us.

Rapid prototyping and 3D printing

As the name implies, rapid prototyping (RP) refers to the rapid manufacture of complex 3D models or physical parts (prototypes) using 3D computer-aided design (CAD) data. It is widely used in product design in some industries and has found a use in the medical and dental fields over the past 30 years. In dentistry it is used specifically for improved and cost-effective diagnosis, treatment planning, and manufacture of certain types of prostheses.¹⁴

Subtractive and additive fabrication methods can be used to manufacture physical prototypes. Whereas subtractive manufacturing is done via numerically controlled machining similar to a milling process to manufacture small objects, additive manufacturing is based on the decomposition of 3D computer model data into thin cross-sectional layers, followed by physical formation and stacking of these layers into 3D forms.¹⁵

The development of computer-aided design and computer-aided manufacturing (CAD/CAM) relies on data acquisition, data processing, and manufacturing. The data in our case were obtained from computer tomography (CT) scans of our patient at 1 mm slice intervals (resolution). The data from the CT scanner were available as DICOM (digital imaging and communications in medicine) files, which have to be converted

into .stl (standard triangulation language) files, to then be used to input into our RP system. For us to do this, we used a computer program known as MIMICS (Materialise interactive medical image control system; Materialise, Leuven, Belgium), which was able to segment the image and provide a clearer representation of our area of interest. This software also allows one to alter the gray-scale values from the DICOM images so as to differentiate between soft tissue and bone.

The segmentation of the CT scans was performed by engineers at the Centre for Rapid Prototyping and Manufacturing (CRPM, Bloemfontein, South Africa), where a team of engineers produced our 3D model on a laser sintering machine (P385, EOS, Krailling, Germany). Selective laser sintering creates 3D models by fusing powdered materials with a carbon dioxide (CO₂) laser. The powdered material, available to us at a thickness of 150 μm, was a polyamide material known as PA2200 (EOS). This is a nylon-based material specifically formulated to meet FDA requirements and is thus suitable for medical use. This powdered material is spread by a roller over the surface of a build cylinder. A piston in the cylinder moves down one object layer thickness at a time to accommodate a new layer of powder. A laser beam traces over the surface of tightly compacted powder, thus elevating the temperature of the powder to its melting point. This then fuses the particles together, and once all the layers are fused together it forms a solid mass, which in our case was our 3D model (Fig 6).

This model was essential to our planning, because we were able to identify the boundaries and fixation areas of our planned titanium frame (implant). The 3D skull data from our CT scans were then imported into another software program, 3-MATIC (Materialise). This program is truly unique in that it is capable of combining CAD tools with pre-processing (meshing) capabilities. It allows one to conduct thorough 3D measurements and analyses, and design implants and surgical guides specific to each patient. This allowed us to design the implant to be manufactured for our patient (Fig 7).

This design was printed in resin on an Objet Connex 350 machine (Stratasys, Frankfurt, Germany) and positioned onto our original 3D model to ensure a precision fit. With our 3-MATIC software we were also able to design a custom drill guide for our surgeons, so that our fixation holes were placed at the correct angulation and where most suitable bone was located. In this process, we arrived at a total of 21 fixating holes that would anchor our implant with 21 corresponding cortical screws (Fig 8).

Our implant design was transferred as an .stl file to a direct metal laser sintering machine (EOSINT M280; EOS), which was able to manufacture our solid implant via a similar laser sintering process out of biocompatible titanium powder (titanium-6Al-4V) of particle size < 40 μm (Fig 9). This implant was trimmed and polished, after which the fitting surfaces of the implant were treated in much the same way as dental implants, including surface abrasion, to achieve possible cortical osseointegration. This procedure involved post machining and thread cutting by Southern Implants (Irene, South Africa). The entire process from design to manufacture took 10 working days, with the cost amounting to around \$5000, for which we obtained sponsorship from our national research foundation, CRPM, and Materialise (Leuven, Belgium).

Our facial implant was placed intraoperatively and fixated as per our design with 21 cortical screws (Fig 10). A poly(vinyl siloxane) impression (President; Whaledent, Cuyahoga Falls, OH) was also taken at this time with the implant in place for the manufacturing of a maxillary denture and a magnet-retained silicone facial prosthesis. After 3 days, the finished maxillary denture's fitting surface was fitted and lined with a soft denture base material (Molloplast-B; Buffalo Dental Manufacturing, Syosset, NY) to act as a shock absorber during function (Fig 11), and our definitive facial prosthesis was delivered (Fig 12).

Conclusion

Malignant peripheral nerve sheath tumors of the trigeminal nerve are exceedingly rare. To our knowledge this is the first case where additive manufacturing techniques were used in manufacturing a custom titanium implant for the reconstruction of an extensive midfacial defect. Our patient has subsequently adapted well to her facial implant and prosthesis, and has been free of recurrent tumor for 6 months.

Acknowledgments

The authors wish to thank Southern Implants (Irene, South Africa) for surface enhancement and sterilization of the implant; The South African National Research Foundation for financial support in acquiring a 3D printer (Objet Connex 350); and Materialise (Leuven, Belgium) for software support.

References

- Schmidt RF, Yick F, Boghani Z, et al: Malignant peripheral nerve sheath tumours of the trigeminal nerve: a systematic review of 36 cases. *Neurosurg Focus* 2013;34:1-10
- Bowers CA, Taussky P, Duhon BS, et al: Malignant peripheral nerve sheath tumour of the trigeminal nerve: a case report and literature review. *Br J Neurosurg* 2011;25:750-753
- Gupta G, Mammis A, Maniker A: Malignant peripheral nerve sheath tumours. *Neurosurg Clin N Am* 2008;19:533-543
- Hajdu SI: Peripheral nerve sheath tumours. Histogenesis, classification, and prognosis. *Cancer* 1993;72:3549-3552
- Chibbaro S, Herman P, Povlika M, et al: Malignant trigeminal schwannoma extending into the anterior skull base. *Acta Neurochir (Wien)* 2008;150:599-604
- Sheitnauer BW, Erdogan S, Rodriguez FJ, et al: Malignant peripheral nerve sheath tumours of cranial nerves and intracranial contents: a clinicopathologic study of 17 cases. *Am J Surg Pathol* 2009;33:325-338
- MacNally SP, Rutherford SA, Ramsden RT, et al: Trigeminal schwannomas. *Br J Neurosurg* 2008;22:729-738
- Minovi A, Basden O, Hunter B, et al: Malignant peripheral nerve sheath tumours of the head and neck: management of 10 cases and literature review. *Head Neck* 2007;29:439-445
- Ducatman BS, Scheithauer BW, Piepgras DG, et al: Malignant peripheral nerve sheath tumours. A clinicopathologic study of 120 cases. *Cancer* 1986;57:2006-2021
- Stark AM, Buhl O, Hugo HH, et al: Malignant peripheral nerve sheath tumours—report of 8 cases and review of the literature. *Acta Neurochir (Wien)* 2001;143:357-364
- Ziadi A, Saliba I: Malignant peripheral nerve sheath tumour of intracranial nerve: a case series review. *Auris Nasus Larynx* 2010;37:539-545
- Cordeiro PG, Chen CM: A 15-year review of midface reconstruction after total and subtotal maxillectomy: part I. Algorithm and outcomes. *Plast Reconstr Surg* 2012;129:124-136
- Futran ND, Mendez E: Developments in reconstruction of midface and maxilla. *Lancet Oncol* 2006;7:249-258
- Sun J, Zhang F: The application of rapid prototyping in prosthodontics. *J Prosthodont* 2012;21:641-644
- Azari A, Nikzad S: The evolution of rapid prototyping in dentistry: a review. *Rapid Prototyp J* 2009;15:216-225